

# *Implantation of SphinKeeper™: a new artificial anal sphincter*

**C. Ratto, L. Donisi, F. Litta,  
P. Campenni & A. Parello**

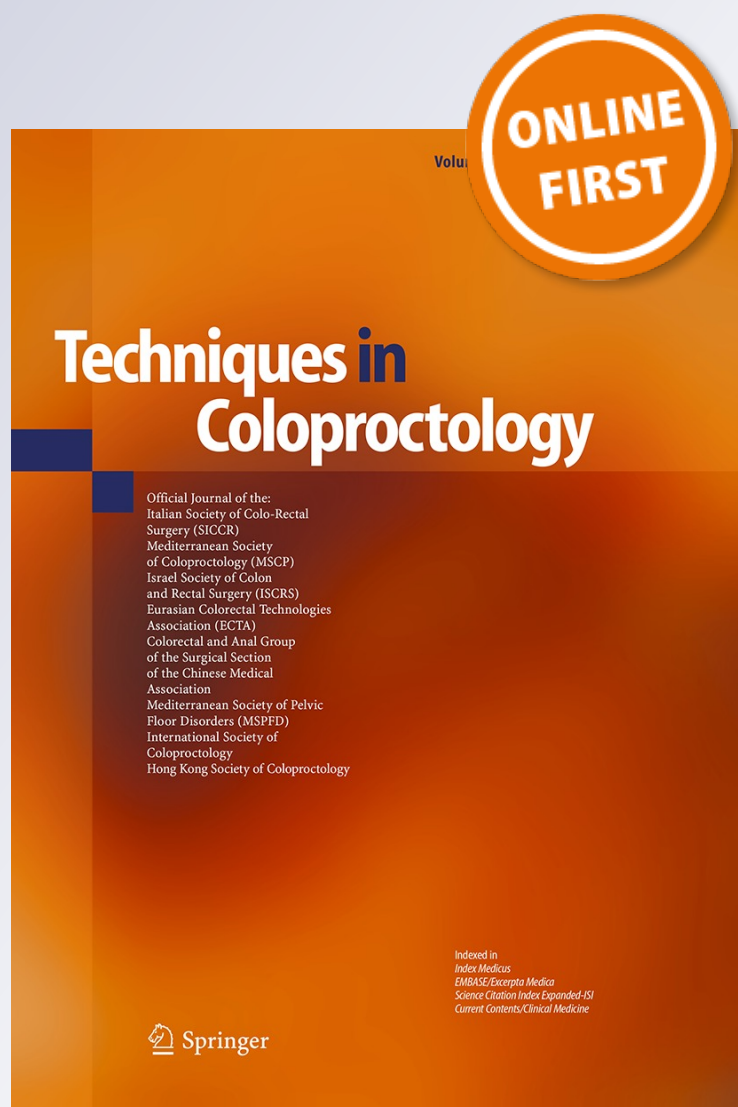
## **Techniques in Coloproctology**

Official Journal of SICCR, MSCP, ISCRS,  
ECTA, Colorectal Anal Group of Surgical  
Section of Chinese Medical Association,  
MSPFD

ISSN 1123-6337

Tech Coloproctol

DOI 10.1007/s10151-015-1396-0



**Your article is protected by copyright and all rights are held exclusively by Springer-Verlag Italia Srl. This e-offprint is for personal use only and shall not be self-archived in electronic repositories. If you wish to self-archive your article, please use the accepted manuscript version for posting on your own website. You may further deposit the accepted manuscript version in any repository, provided it is only made publicly available 12 months after official publication or later and provided acknowledgement is given to the original source of publication and a link is inserted to the published article on Springer's website. The link must be accompanied by the following text: "The final publication is available at [link.springer.com](http://link.springer.com)".**

# Implantation of SphinKeeper<sup>TM</sup>: a new artificial anal sphincter

C. Ratto<sup>1</sup> · L. Donisi<sup>1</sup> · F. Litta<sup>1</sup> · P. Campenni<sup>1</sup> · A. Parello<sup>1</sup>

Received: 3 August 2015 / Accepted: 30 October 2015  
© Springer-Verlag Italia Srl 2015

## Abstract

**Introduction** A new artificial anal sphincter, SphinKeeper<sup>TM</sup>, was devised with the aim to treat fecal incontinence (FI) by implanting specifically designed self-expandable prostheses into the intersphincteric space. Preliminary data concerning the procedure feasibility and prosthesis localization at 3 months are presented.

**Methods** SphinKeeper<sup>TM</sup> prostheses in the native state are dehydrated, thin, solid cylinder (length 29 mm, diameter 3 mm), changing their state (shorter—length 23 mm, thicker—diameter 7 mm—and softer, with shape memory) within 48 h of contact with fluids. In this study, 10 prostheses were implanted in each patient with FI under local anesthesia and under endoanal ultrasound (EAUS) guidance, into the upper-middle intersphincteric space of the anal canal by a specifically designed delivery system. EAUS was used postoperatively to assess prostheses dislocation.

**Results** Ten patients (5 females; median age 58 years, range 20–75) were enrolled and treated with SphinKeeper<sup>TM</sup> implantation. Median duration of procedure (performed by endoanal ultrasound guidance) was 40 min (range 30–45). Neither intraoperative nor postoperative complications were reported after a 3-month follow-up. In one patient, a partial dislocation of a single prosthesis was documented by EAUS, causing anal discomfort which resolved after 1 week.

**Conclusion** SphinKeeper<sup>TM</sup> can be safely implanted in patients with FI of different etiology. Implantation was well tolerated with no dislodgment of implants at 3-month follow-up.

**Keywords** Fecal incontinence · Artificial anal sphincter · Sphincter lesion · Sacral nerve stimulation · Sphincteroplasty · Bulking agents · Gatekeeper · Dynamic graciloplasty

## Introduction

Multifactorial etiology of fecal incontinence (FI) has a significant impact on the choice of management [1–3]. Sphincter lesions are considered to be the main cause of FI, particularly in female patients, but frequently the dysfunction occurs also in subjects with intact sphincters. In other cases, neuropathy (either peripheral or central) plays the pivotal role, causing sensory-motor alterations [2–7]. Also the severity of FI can be variable, ranging from soiling, seepage and incontinence to gas (commonly defined as “minor incontinence”) to incontinence to liquid and solid stools (defined as “major incontinence”). Despite the numerous modalities of treatment available, the therapeutic efficacy is still suboptimal for all of them. In fact, “conservative” therapies such as biofeedback have high failure rates while the success of “minimally invasive” procedures such as injectable bulking agents, radiofrequency, tibial and sacral nerve stimulation or “aggressive” procedures such as anal sphincteroplasty, graciloplasty, artificial bowel sphincter and magnetic sphincter range from partial success to complete failure [8].

A new artificial anal sphincter, SphinKeeper<sup>TM</sup>, was devised with the aim to surround the anal canal with specifically designed self-expandable prostheses placed into the intersphincteric space. Here we report the safety data and the short term ultrasound assessment after implantation of this device in patients with FI.

✉ C. Ratto  
carloratto@tiscali.it

<sup>1</sup> Proctology Unit, Department of Surgical Sciences, Catholic University, Largo A. Gemelli, 8, 00168 Rome, Italy

## Materials and methods

SphinKeeper™ prostheses (THD SpA, Correggio, Italy) are made of hyexpan (polyacrylonitrile), which was previously used for the same purpose in the Gatekeeper™ (THD SpA, Correggio, Italy) [9, 10]. SphinKeeper™ prostheses in the dehydrated state are, thin, solid cylinder (length 29 mm, diameter 3 mm), changing their size (shorter—length 23 mm, thicker—diameter 7 mm) and physical properties (softer, with shape memory) within 48 h of contact with fluids (Fig. 1).


Patients were included in this study according to the following criteria: older than 18 years and younger than 80 years, FI onset at least 6 months before the implant, a number of FI episodes more than once a week and willingness to perform baseline and follow-up schedule evaluations and to sign an informed consent. Exclusion criteria were: malignancies under treatment, rectal bleeding of unknown origin, chronic diarrhea unresponsive to medical treatment, inflammatory bowel disease unresponsive to medical treatment, acute anorectal sepsis, concomitant rectal prolapse, obstructive defecation syndrome, neurological disease, coagulation disorder. At baseline, patients were evaluated on the base of detailed medical history and physical examination; when indicated, a colonoscopy was performed. Particular attention was paid to investigate previous surgery, trauma and/or local radiotherapy, congenital anorectal malformations, comorbidity, FI symptoms, characteristic and diary, ability to defer defecation, need to wear pads and/or taking constipating drugs, Cleveland Clinic Fecal Incontinence Score (CCFIS), Vaizey score, AMS score [11–13]. Health status and quality of life were evaluated with SF-36 and FIQL, respectively [14, 15]. Anorectal manometry (ARM) and endoanal ultrasound (EAUS) were performed to assess the anorectal function and morphology.

The aim of this study was to record of intra- postoperative adverse events in order to obtain data about technical feasibility and safety. Intra- and postoperative complications were prospectively collected, in particular looking at clinical and/or EAUS evidence of bleeding at/from the sites of implantation, anorectal sepsis (anorectal abscess and/or fistula), signs of local and systemic inflammation, pain, duration of analgesics therapy and urinary retention. Prosthesis were checked with EAUS at 1 week, 1 month and 3 months for dislocation.


## Operative procedure

Patients underwent standard bowel preparation with two 120 ml docusate sodium enemas, one the night before and one few hours before the operation. Antibiotics prophylaxis was given as 1 g of i.v. Cefazolin and 500 mg of i.v. Metronidazole. All implant procedures were performed with the patient in lithotomy position, under local anesthesia using a Mepivacaine perineal block. Skin was prepped with povidone iodine solution. The entire procedure was carried out under EAUS guidance. The delivery system (Fig. 2) was loaded before each insertion. Before insertion an activating button was pushed for 5 s resulting in the extrusion of a guiding cannula. Ten 2-mm perianal skin incisions were made 2 cm from the anal margin, equidistant each other. Under digital guidance, the introducer was inserted into the intersphincteric space through a short subcutaneous tunnel and pushed up to reach the upper part of the anal canal. EAUS confirmed the correct position of the cannula into the intersphincteric space and the tip of the introducer at the level of the upper third of the anal canal. Once in place the gun was fired resulting in a retraction of the cannula and deployment of the prosthesis. When the proximal part of the prosthesis reaches the tip of the cannula, the whole cannula completely retracts inside the delivery system and the prosthesis is released in place in the desired position within the intersphincteric space. The delivery device was withdrawn. EAUS is used to confirm the position of the prosthesis, which appears as an hyperechoic dot with a hypoechoic shadow behind it. Three-dimensional EAUS was used by our group and showed a continuous hyperechoic line. The same procedure was repeated for all 10 prostheses around the entire circumference of the internal anal sphincter (Fig. 3). At the end of the procedure, a final 3D-EAUS imaging was carried out as final assessment (Fig. 4). Finally, skin wounds were sutured with resorbable material. Repeated EAUS at 1-week documented the final dimensions of the prosthesis (Fig. 4). All patients were strongly advised to observe bed rest or slowly move out of bed to chair for 48 hours to minimize early prosthesis dislocation. Lidocaine gel and systemic painkillers (ibuprofen and tramadol) were prescribed as needed for postoperative pain.

**Fig. 1** Sphinkeeper™ prosthesis as appears in the native, dehydrated condition (a) and following hydration (b)



**Fig. 2** Sphinkeeper™ delivery system, showing, in detail, the dispenser containing the prosthesis



**Postoperative evaluation and follow-up**

Clinical evaluation (comprehensive of FI symptoms, continence diary, FI severity scores—CCFIS, Vaizey and AMS, FIQL and SF-36 questionnaires, physical examination and EAUS) was scheduled at 1 week, 1 month and 3 months after SphinKeeper implant. All patients were informed about the importance of avoiding constipation and hard stool; a diet rich in water and fibers, and oral assumption or stool softeners were prescribed during the first postoperative month.

**Results**

In the period between July 2014 and April 2015, 10 consecutive patients (5 men; 5 females) with a median age of 58 years (range 20–75), who met the inclusion criteria, were enrolled in the present pilot study and treated with SphinKeeper™ implantation. Table 1 summarizes the baseline patients' characteristics, including data from clinical history, FI severity scores, previous management of FI, health status and quality of life of the enrolled patients.

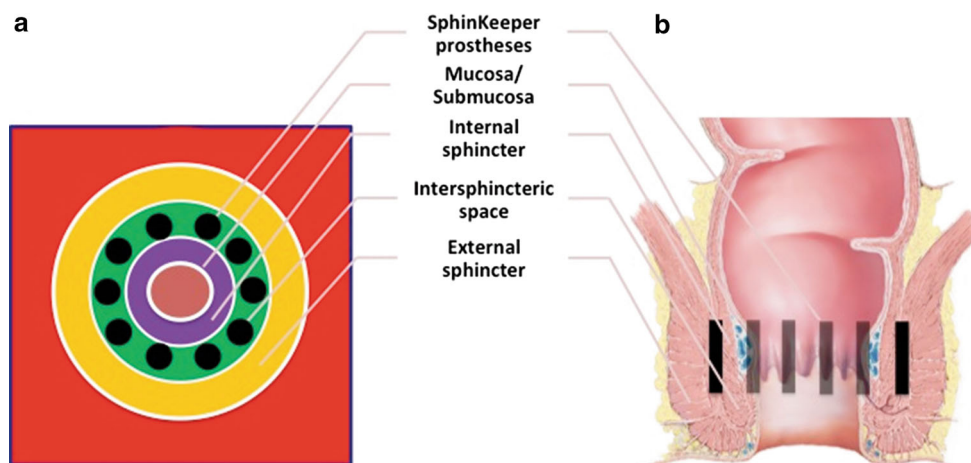
Minimum duration of FI was 3 years, while the median duration was 9 years. Four patients referred passive FI, 4 urge FI and 3 mixed FI. Seven patients had undergone perineal surgical procedures, and 3 of them previous surgery for FI. One patient had undergone pelvic radiotherapy for endometrial cancer. Nine patients used pads daily. Baseline ultrasonography and manometry data are reported, respectively, in Tables 2 and 3.

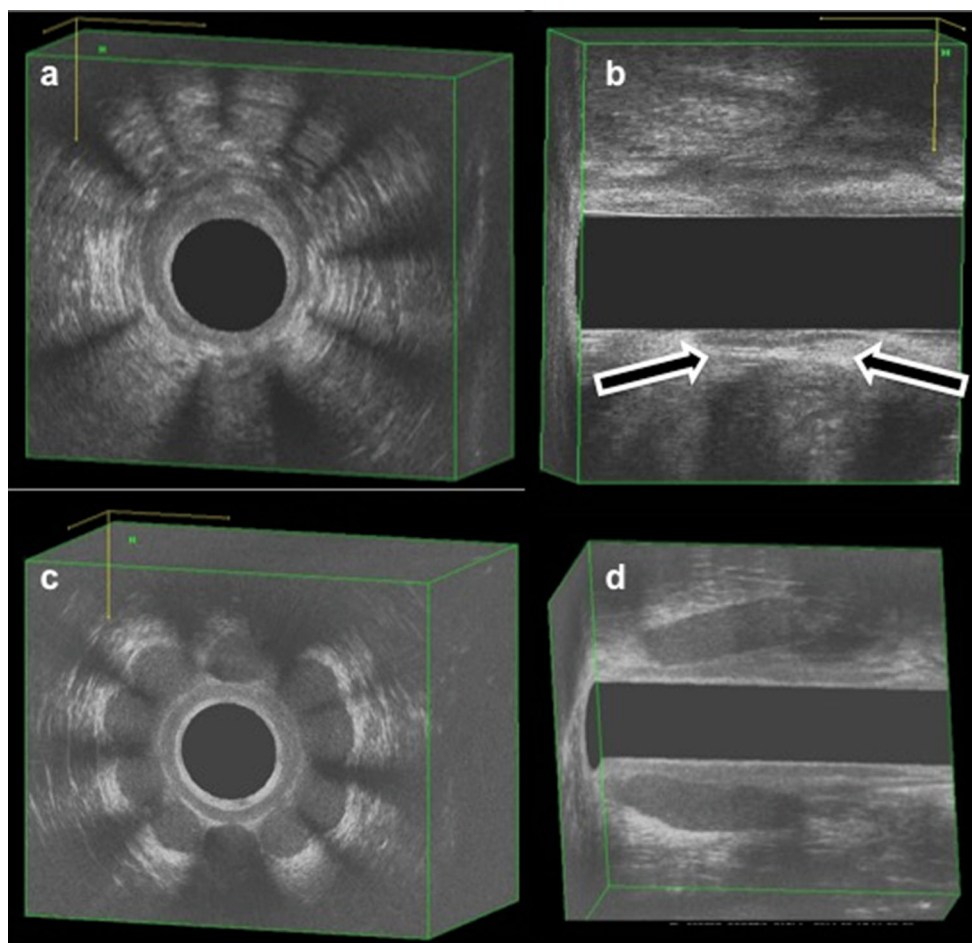
Median operative time for SphinKeeper™ implantation under EAUS guidance was 40 min (range 30–45). Neither intraoperative nor early postoperative complications were reported during the hospital stay.

At 1-week EAUS evaluation, all the prostheses reached their final size, even those implanted in scar tissue (Fig. 5). At one week, one patient complained of anal discomfort that, at digital examination and EAUS evaluation, was attributed to a 1 cm distal dislocation of a single prosthesis within the intersphincteric space, which was treated by local and systemic painkillers (lidocaine 2 % gel and paracetamole 1 gr tablets) until the resolution of symptoms one week from the onset.

All patients completed the follow-up evaluation at 1 week, 1 month and 3 months. There was no postoperative morbidity, in particular in terms of obstruction to the

**Fig. 3** Site of Sphinkeeper™ implantation within the intersphincteric space





**Fig. 4** 3D-endoanal ultrasound showing the implanted SphinKeeper™ prostheses as imaged at the end of operation (**a, b**) and 1 week after (**c, d**)

passage of stool, bleeding, anorectal sepsis, abscess or fistula, local or systemic symptoms or chronic pain requiring analgesics. During follow-up evaluation, no additional case of prosthesis dislocation, extrusion or migration was detected.

## Discussion

Our study shows that SphinKeeper™ implantation is not followed by septic or adverse reactions, does not result in short-term dislodgement and is well tolerated. This is promising, given the size, number, site of deployment and elastic property of the prostheses, which are novel and discussed below. Functional results and quality of life are not the scope of this report given the short follow-up of 3 months.

SphinKeeper™ is the result of multiple innovations in the treatment of FI, concerning both the device and the implantation procedure therefore deserving the title

definition of “new artificial anal sphincter.” In terms of biomechanics, SphinKeeper™ prostheses are made of a material which has already been clinically tested [9, 10] and has the ability to rapidly (within 2 days) self expand as well as shape memory. Because of these characteristics, the prostheses, even if inert have the potential to change in shape with stool passage through the anal canal (because soft and compressible), and regain shape and size afterwards. This mechanism of action can be particularly useful when the prostheses are placed into the upper and middle anal canal, where, physiologically, the recto-anal inhibitory reflex is elicited, starting the cascade of defecation events. On the other hand, no obstruction developed during the stool passage, as demonstrated in the present study.

Prostheses fit well into the anal canal. They are long enough (23 mm in the final length) to reconstitute the normal anal canal length and wide enough (7 mm in the final diameter) to ensure a significant filling ability. Moreover, the documented expansion of SphinKeeper prostheses also within the scar tissue could give the

**Table 1** Baseline patients' characteristics

Patients' characteristics	Data
No. of patients	10
No. of females (%)	5 (50)
Median age (years; range)	70 (20–75)
Median age of FI onset (years; range)	53 (1–70)
Median duration of FI (years; range)	9 (3–21)
Soiling <sup>a</sup>	7 (2–49)
Gas <sup>a</sup>	14 (0–35)
Liquid stool <sup>a</sup>	3 (0–21)
Solid stool <sup>a</sup>	0 (0–7)
CCFI score	10 (5–17)
Vaizey score	13 (7–16)
AMS score	80 (26–114)
No. of patients with urinary incontinence	4
No. of patients with previous pelvic trauma	0
No. of patients with previous radiotherapy	1
No. of patients with diabetes	0
No. of patients with endocrine disease	0
No. of patients with neurological disease	0
No. of patients with gynecological disease	1
No. of patients with congenital anorectal malformation	1
No. of patients with inflammatory bowel disease (in long term remission phase)	1
History (no. of patients)	
Anal surgery	4
Fistulotomy/fistulectomy	2
Perineal rectopexy	1
Correction of anorectal congenital malformation	1
Abdominal surgery	2
Anal trauma	0
FI surgery	3
Sphincteroplasty	1
SNS	1
Gatekeeper implant	1
Quality of life [median value (range)]	
SF-36 <sup>®</sup>	
Physical function	55 (45–90)
Role physical	25 (0–100)
Bodily pain	74 (12–90)
General health	67 (40–77)
Vitality	60 (35–75)
Social function	75 (37.5–87.5)
Role emotional	33.3 (0–100)
Mental health	68 (40–92)
FIQL score	
Lifestyle	3.2 (2.1–3.8)
Coping and behavior	2.0 (1.2–2.9)
Depression and self-perception	3.6 (2.1–3.9)
Embarrassment	2.3 (2.0–4.0)

CCFI score Cleveland Clinic Fecal Incontinence Score, AMS score American Medical System Score, FI Fecal Incontinence, SNS Sacral Nerve Stimulation

<sup>a</sup> Median number of episodes per week (range)

**Table 2** Endoanal ultrasound basal features

Features	No of patients
Internal anal sphincter lesion	3
External anal sphincter lesion	4
Internal anal inhomogeneity	5
External anal inhomogeneity	5

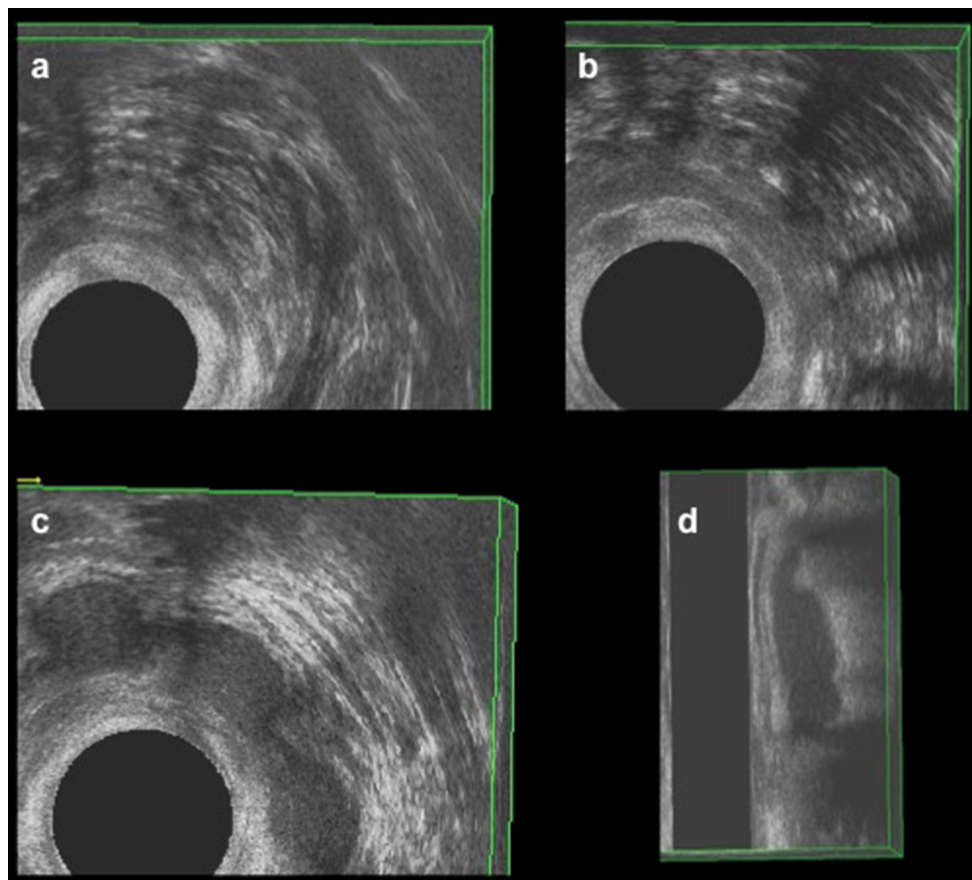
**Table 3** Anorectal manometry basal data [median (range)]

ARM parameters	Features
Maximum resting pressure (mmHg)	41.5 (19.7–184.3)
Maximum squeeze pressure (mmHg)	100.9 (10.8–316.0)
Functional anal canal length (cm)	0.9 (0.8–1.3)
Threshold rectal sensation (ml)	60 (30–60)
Urge rectal sensation (ml)	100 (55–220)
Rectal maximum tolerated volume (ml)	180 (90–290)

opportunity to treat also patients with sphincter defects. These aspects should be further investigated in large number of patients.

The SphinKeeper<sup>TM</sup> procedure provides the implantation of 8–12 prostheses (always 10 in the present study). The prosthesis is made of a material which has been prospectively tested in the setting of fecal incontinence [9, 10], and has the advantage of being easily visualized by ultrasound. This allows the operator to choose accurately the implant site before the prosthesis release and, then, activate the mechanism of delivery. The insertion and deployment of each prosthesis takes only a few seconds.

The choice to implant the prostheses into the intersphincteric space of the anal canal plays a key role. This location potentially avoids extrusion or migration of prostheses (differently than if implanted into the submucosa). Moreover, thanks to the rapid increase of their volume, the prostheses are unlikely to move after deployment. The bed rest which was recommended in this pilot study is aimed at decreasing the event of an early prosthesis dislocation (which occurred in one out of 100 prostheses implanted in this study). As far as postoperative complications SphinKeeper<sup>TM</sup> implant was very safe in this study; in fact, no acute sepsis at the site of implantation and around the prostheses was documented within 90-day period. No



**Fig. 5** 3D-endoanal ultrasound showing the implanted Sphinkeeper<sup>TM</sup> prostheses in a patient with sphincter lesion, imaged at the end of operation (a, b) and within 1 week after (c, d)



patient had long-lasting symptoms (including anorectal pain and discomfort) directly or indirectly related to the implanted prostheses. This confirmed what was already observed in a large population submitted to another type of implantation of this material into the anal canal [9, 10]. Specifically in the case of SphinKeeper™, a high number of prostheses are implanted reaching a very high final volume of implanted material (8650 mm<sup>3</sup>, approximately 480 % increase in size of the native sphincter), surrounding the anal canal and playing the role of an “additional” sphincter. The changes in the sphincter anatomy confirmed by imaging are expected to play a physiologic role. The hypothetical positive interaction between the SphinKeeper™ prostheses and the adjacent IAS and EAS is interesting. Under physiological conditions, central input (neural drive to the muscle) and muscle length (microscopically, sarcomere length) are the key determinants of tension and force generated by the skeletal muscles [16]. It has been well demonstrated that EAS muscle operates at a short sarcomere length in both rabbits and humans; in other words, increasing its in vivo length increases its contraction [17–21]. Our hypothesis is that the large volume SphinKeeper™ implants, placed between EAS and IAS (pushing the EAS outwards and the IAS inwards), may increase the muscle fibers length and, therefore increase their contractility. Further studies will definitely elucidate this mechanism of action.

These properties make of SphinKeeper™ an attractive alternative to the “external” artificial anal sphincters (ABS, i.e., artificial bowel sphincter, dynamic graciloplasty, slings, magnetic anal sphincter). In fact, in the case of ABS and dynamic graciloplasty, only the release of the closure system, operated by the patient, can permit the defecation, while, in the case of anal slings and magnetic anal sphincter, the pressure of the rectal content allows the anal canal opening. We hypothesize that, SphinKeeper™, as embedded into the anal canal, may improve sphincter contractility by increasing sarcomere length as well as increase the length of the anal canal and provide a powerful “bulking effect.”

Following our hypothesis, in patients with loose, patulous, funnel-like or keyhole-shaped anal canal, SphinKeeper™ could offer the opportunity to reconstitute the cylindrical shape of the anal canal, while in patients with sphincteric lesions it could reinforce the area of scarring improving the contribution to the continence by the remaining intact sphincters. Finally, not insignificant could be the role played by SphinKeeper™ as adjunctive therapy in patients with incomplete resolution of symptoms after other procedures for FI. In conclusion, implantation of the SphinKeeper™ is feasible in patients with different types of FI and does not give rise to major complications or dislodgement. If proved effective it may be a viable, minimally invasive first line approach in patients suffering from FI.

## Compliance with ethical standards

**Conflict of interest** The authors declare that they have no conflict of interest.

**Ethical approval** All procedures performed in studies involving human participants were in accordance with the ethical standards of the institutional and/or national research committee and with the 1964 Helsinki declaration and its later amendments or comparable ethical standards.

**Informed consent** Informed consent was obtained from all individual participants included in the study.

## References

- Paquette IM, Varma MG, Kaiser AM, Steele SR, Rafferty JF (2015) The American Society of Colon and Rectal Surgeons' clinical practice guideline for the treatment of fecal incontinence. *Dis Colon Rectum* 58:623–636
- Hayden DM, Weiss EG (2011) Fecal incontinence: etiology, evaluation, and treatment. *Clin Colon Rectal Surg* 24:64–70
- Hull T (2007) Fecal incontinence. *Clin Colon Rectal Surg* 20:118–124
- Brown HW, Wexner SD, Segall MM, Brezoczky KL, Lukacz ES (2012) Accidental bowel leakage in the mature women's health study: prevalence and predictors. *Int J Clin Pract* 66:1101–1108
- Brown HW, Wexner SD, Lukacz ES (2013) Factors associated with care seeking among women with accidental bowel leak-age. *Female Pelvic Med Reconstr Surg* 19:66–71
- Bharucha AE, Fletcher JG, Melton LJ, Zinsmeister AR (2012) Obstetric trauma, pelvic floor injury and fecal incontinence: a population-based case-control study. *Am J Gastroenterol* 107:902–911
- Nelson RL (2004) Epidemiology of fecal incontinence. *Gastroenterology* 126:S3–S7
- Van Koughnett JA, Wexner SD (2013) Current management of fecal incontinence: choosing amongst treatment options to optimize outcomes. *World J Gastroenterol* 19:9216–9230
- Ratto C, Parello A, Donisi L et al (2011) Novel bulking agent for faecal incontinence. *Br J Surg* 98:1644–1652
- Ratto C, Buntzen S, Aigner F et al (2015) Multicentre observational study of Gatekeeper for faecal incontinence. *Br J Surg*. doi:10.1002/bjs.10050
- Jorge JMN, Wexner SD (1993) Etiology and management of faecal incontinence. *Dis Colon Rectum* 36:77–97
- Vaizey CJ, Carapeti E, Cahill JA, Kamm MA (1999) Prospective comparison of faecal incontinence grading systems. *Gut* 44:77–80
- American Medical Systems Fecal incontinence scoring system (1996) American Medical Systems, Minnetonka
- Ware JE Jr, Sherbourne CD (1992) The MOS 36-item short-form health survey (SF-36). I. Conceptual framework and item selection. *Med Care* 30:473–483
- Rockwood TH, Church JM, Fleshman JW et al (2000) Fecal incontinence quality of life scale: quality of life instrument for patients with fecal incontinence. *Dis Colon Rectum* 43:9–16 (discussion 16–17)
- Gordon AM, Huxley AF, Julian FJ (1966) The variation in isometric tension with sarcomere length in vertebrate muscle fibres. *J Physiol* 184:170–192
- Rajasekaran MR, Jiang Y, Bhargava V et al (2008) Length-tension relationship of the external anal sphincter muscle:

- implications for the anal canal function. *Am J Physiol Gastrointest Liver Physiol* 295:G367–G373
18. Rajasekaran MR, Jiang Y, Bhargava V, Ramamoorthy S, Lieber RL, Mittal RK (2011) Sustained improvement in the anal sphincter function following surgical plication of rabbit external anal sphincter muscle. *Dis Colon Rectum* 54:1373–1380
  19. Mittal RK, Sheean G, Padda BS, Lieber R, Rajasekaran MR (2011) The external anal sphincter operates at short sarcomere length in humans. *Neurogastroenterol Motil* 23:643 (**e258**)
  20. Rajasekaran MR, Jiang Y, Bhargava V, Lieber RL, Mittal RK (2011) Novel applications of external anal sphincter muscle sarcomere length to enhance the anal canal function. *Neurogastroenterol Motil* 23:70–75 (**e7**)
  21. Kim YS, Weinstein M, Raizada V et al (2013) Anatomical disruption and length-tension dysfunction of anal sphincter complex muscles in women with fecal incontinence. *Dis Colon Rectum* 56:1282–1289